

# Type 2 Diabetes Mellitus, Hippocampus And Memory

Asem Veeves Singh<sup>1</sup>, Anand Vijayakumar Palur Ramakrishnan<sup>2</sup>, Salam Ranabir<sup>3</sup>,  
Tashi Chhojom Khom<sup>4</sup>, Sarath Chandran K R<sup>5</sup>, Japheth Thono<sup>6</sup>, Lalrinchani<sup>7</sup>

<sup>1</sup>Pharm D, Research Scholar, Department of Pharmacology, JSS College of Pharmacy, PB No: 20, 001, E-mail ID: [veeves26@gmail.com](mailto:veeves26@gmail.com)

<sup>2</sup>Ph.D. Professor, Department of Pharmacology, JSS College of Pharmacy, PB No: 20, Rocklands, Udhagamandalam-643 001, E-mail ID: [pranandvijayakumar@gmail.com](mailto:pranandvijayakumar@gmail.com)

<sup>3</sup>M.D., D.M., (Endocrinology) Associate Professor, Department of General Medicine, Regional Institute of Medical Sciences (RIMS), Lamphelpat, Imphal - 795 005, Manipur, India., E-mail ID: [salamranabir@yahoo.co.in](mailto:salamranabir@yahoo.co.in)

<sup>4</sup>Assistant Professor Himalayan University, Itanagar – 791111, E-mail ID: [tashinu@yahoo.com](mailto:tashinu@yahoo.com)

<sup>5</sup>PGT, Department of General Medicine, Regional Institute of Medical Sciences (RIMS), Lamphelpat, Imphal - 795 005, Manipur, India., E-mail ID: [sarathkr1993@gmail.com](mailto:sarathkr1993@gmail.com)

<sup>6</sup>PGT, Department of General Medicine, Regional Institute of Medical Sciences (RIMS), Lamphelpat, Imphal - 795 005, Manipur, India., E-mail ID: [japheththono@gmail.com](mailto:japheththono@gmail.com)

<sup>7</sup>PGT, Department of General Medicine, Regional Institute of Medical Sciences (RIMS), Lamphelpat, Imphal - 795 005, Manipur, India. E-mail ID: [rinchhanifanai10@gmail.com](mailto:rinchhanifanai10@gmail.com)

## Abstract

There is strong evidence of type 2 diabetes mellitus-associated hippocampal atrophy. Insulin resistance, poor HbA1c level control, oxidative stress, vascular complication, higher cortisol levels and neuroinflammation in diabetes mellitus contribute to the reduction of hippocampus volume. The hippocampus plays an important role in the storage and retrieval of declarative memory. The hippocampus volume reduction could trigger declarative memory impairment. The present review article aims to provide an overview of the impact of type 2 diabetes mellitus on the hippocampus and its effect on memory.

**Keywords:** Type 2 diabetes mellitus, hippocampus, memory.

## Introduction

As a result of high-calorie diets and sedentary lifestyles, the global prevalence of diabetes mellitus is increasing. The ageing population is also an essential factor contributing to the increasing prevalence of diabetes mellitus. Diabetes mellitus is an endocrine disorder characterized by inadequate insulin secretion by beta-cells ( $\beta$ -cells) of the pancreas or resistance by skeletal muscles towards the secreted insulin. According to International Diabetes Federation (IDF) 2017, 425 million people worldwide have diabetes, estimated to affect 629 million people by 2045. The second-highest number of people with diabetes in the world is in India (69.2 million), which is hypothesized to increase to 123.5 million by 2040. (1) The data states that diabetes mellitus is more prevalent in developing countries, a big

reason for worry. T2DM is an emerging chronic complication faced by humans, a cause of concern to the healthcare system, by accommodating an enormous economic burden.

According to global statistics among all types of diabetes, around 90% of cases were contributed by type 2 diabetes mellitus (T2DM). (1) Epidemiological studies have associated type 2 diabetes mellitus with increased risk of cognitive impairment, from mild cognitive impairment (MCI) to dementia. (2-6) T2DM has been associated not only with subtle cognitive deficits like mental speed and flexibility but also with an increased risk for developing significant disruptive cognitive function in memory decrement. (7-10) T2DM is well known for its adverse impacts on the

hippocampus, leading to memory deficits. (11,12)

The human brain is one of the sophisticated organs in our body that can accumulate past information and are capable of remembering it either consciously or unconsciously. Human memories entail biological strategies and anatomical substrates. The brain system is interconnected to each other, and it will be an injustice to think about the function of a small part of it in isolation.

The hippocampus is part of the brain system that plays a critical role in remembering declarative memory or explicit memory. (13) An individual gathers information on declarative memory when consciously aware of what is happening in their surroundings. Declarative memory is the form of memory that is associated with facts and events. (14)

In this review, we address the impact of T2DM manifestation related to the hippocampus. We emphasized Hippocampus and T2DM, but we also highlighted hippocampus-associated memory. We included the studies on T2DM hippocampal atrophy and T2DM risk factors

underlying hippocampal atrophy; however, many questions' answers remain unclear.

## T2DM

T2DM is a chronic metabolic disorder with an elevated plasma glucose level for a prolonged period due to increased hepatic glucose production, insulin resistance, and abnormal pancreatic  $\beta$ -cells function. Insulin resistance is considered a primary pathophysiologic disorder in T2DM. Insulin resistance is a metabolic state with an abnormal expression of insulin receptor response towards the insulin produced. (15) The specific pathway involved in  $\beta$ -cells dysfunction is ambiguous, though inherited genetic and acquired factors such as obesity, sedentary lifestyle and ageing are considered to be the prominent causes. Impaired glucose tolerance, generally termed prediabetes, proceeds to T2DM. T2DM constitutes a heterogeneous constellation of disease syndromes that end with the final result of hyperglycemia.

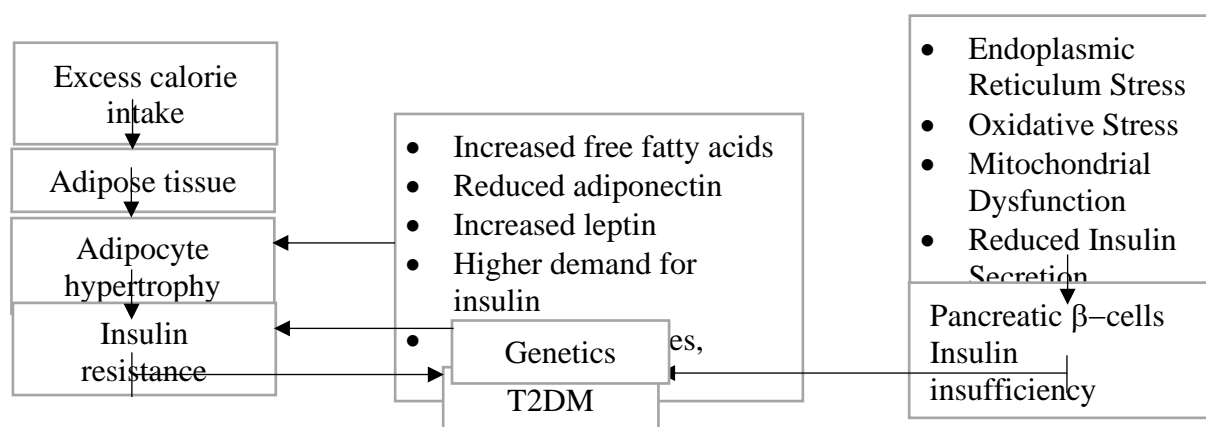


Figure 1: Factor contributing to insulin resistance and  $\beta$ -cells dysfunction in T2DM

## Hippocampus

The hippocampus is involved in the mechanism for archiving and remembering the episodic memory of events. (16-18)

The hippocampus lies in the medial temporal lobe of the brain. The hippocampus is three nested C-shaped arches surrounding the diencephalon and basal ganglia. Anatomically hippocampus can be divided into three segments, the head, the body and the posterior

tail. A hippocampal formation is a group of brain regions consisting of the dentate gyrus, hippocampus, subiculum, presubiculum, parasubiculum and entorhinal cortex (Fig. 2). Giulio Cesare Aranzi, a Bolognese anatomist was the first to coin the name "Hippocampus". (19) The Latin word hippocampus was derived from the Greek word hippokampos (hippos meaning "horse" and kampos meaning "sea monster").

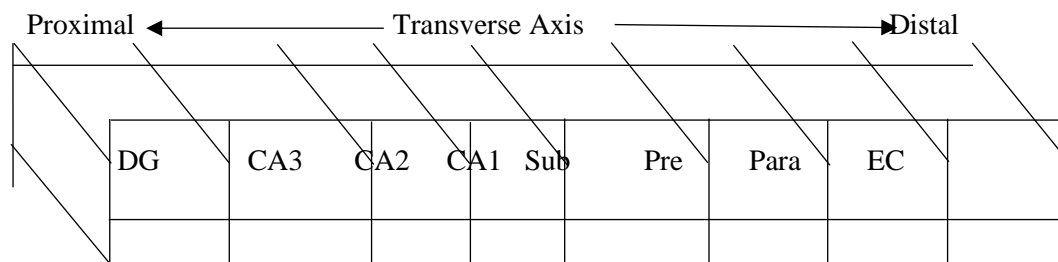


Figure 2: Projections along the transverse axis of the hippocampal formation, the dentate gyrus is located proximally and the entorhinal cortex distally (20)

Advance in magnetic resonance imaging (MRI) spatial resolution and automated segmentation algorithm by applying ultra-high resolution and ex-vivo MRI references makes the measurement of hippocampal subfields volume accurate. Anatomically hippocampus consists of Cornu Ammonis (CA), dentate gyrus, and subiculum. (21) The coronal section of the hippocampus body is "U" in shape and is composed of gray matter: the Ammon horn and the dentate gyrus. The Ammon horn is subdivided into histologically defined four regions designated as CA1, CA2, CA3, and CA4. The term hippocampus is reserved for the CA field's hippocampal formation. Hippocampus Ammons horn or Conus Ammonis was named after the Egyptian god Amun Kneph, whose symbol resembles a ram. (22) Many theories, terminology and synonyms have been applied to the hippocampus region though the exact border between the several regions of hippocampal formation has not been appropriately defined. The dentate gyrus is a particular region of "U" shape, which is similar in shape entirely through the hippocampal formation. Lorente de N6 divided the hippocampus into CA3, CA2, and CA1. He defines the CA2 field as a narrow cell zone between the CA3 and CA1 fields. He also defines the CA4 field as the deep layer of the dentate gyrus. (23) The hippocampus always includes the subiculum as the distinct subiculum region in MRI scans is indistinguishable from the CA field.

### T2DM and Hippocampus

T2DM is related to decrements in cognition, particularly learning and memory deficits. (24) Hippocampus plays a vital role in the learning and memory domain. Several studies have reported the association between accelerated hippocampal atrophy in T2DM (Table 1). The pathogenesis linking T2DM and hippocampal atrophy is not

entirely established. Insulin resistance and poor HbA1c level control contribute to the reduction of hippocampus volume. Insulin resistance may result in a high concentration of insulin receptors in the hippocampus leading to hippocampal neuronal loss. (25) Insulin resistance and inactivation of insulin receptors reduced neuronal plasticity leading to brain deformation. (26,27) Neural ageing and neurodegeneration are associated with T2DM as chronic hyperinsulinemia mediates the downregulation of insulin receptors at Blood-Brain Barrier (BBB), reducing brain insulin levels. (28) Changes in Hippocampal CA1 and subiculum region could also be the reason for memory impairment in T2DM. (16)

Oxidative stress leads to the formation of radicals by non-enzymatic glycation of proteins, glucose oxidation and increased lipid peroxidation, causing damage to enzymes and cellular machinery and also increased insulin resistance in T2DM. (29,30) Amyloid precursor protein (APP) and amyloid- $\beta$ -peptide ( $A\beta$ ) affect mitochondrial activity and increase oxidative stresses, which can impede the glucose metabolic pathway. (31) Thus, oxidative stress plays an important role in the development of memory impairment among T2DM.

The vascular complication in T2DM increases the risk of neuropsychological impairment by altering blood flow regulation in cerebral microvasculature, affecting neurovascular coupling and hemodynamic response function. (32) T2DM have been known to increase the ventricular volume with increased temporal horn volume of the lateral ventricle, which are the markers of hippocampal atrophy. (33,34) Pericytes, the central nervous system's mural cells, help maintain the BBB. Oxidative stress and increased level of amylin or islet amyloid polypeptide are the potential cause of pericyte loss in T2DM, leading to BBB permeability and breakdown. (35) Cortisol is a steroid hormone that plays a critical role in glucose regulation. Poorly maintained glucose levels in T2DM result in hyperactivation of the hypothalamic-pituitary-adrenal axis

Author	Sample (N)	Age (Year)	Hippocampus Volume	Result
F. C. G. Vassem Bussel et al., (40)	T2DM: 40 Participants without T2DM: 38	40 - 47	T2DM hippocampal volume (cm <sup>3</sup> ): Left - 3.8 (0.5) Right - 4.0 (0.5) Participants without T2DM hippocampal volume (cm <sup>3</sup> ): Left - 4.0 (0.4) Right - 4.1 (0.4)	T2DM participants have smaller hippocampal volumes compared to participants without T2DM
Yan-Wei Zhang et al., (41)	T2DM: 80 Control: 80	T2DM: 57.49 (9.04) Control: 57.83 (10.31)	T2DM hippocampal volume (mm <sup>3</sup> ): Left - 3485.38 (391.75) Right - 3627.81 (298.21) Control hippocampal volumes (mm <sup>3</sup> ): Left - 3599.69 (414.47) Right - 3748.90 (435.63)	The hippocampal volumes were smaller in T2DM patients, mainly in the CA1 and subiculum subfields
Kumi Hayashi et al., (42)	T2DM: 61 Subjects: 53	T2DM: 74 ± 7. Subjects: 74 ± 5	Hippocampal atrophy (%): T2DM - 2.13 ± 1.18 Subjects - 1.52 ± 0.73	The study showed hippocampal atrophies to be more frequent in elderly Japanese patients with T2DM than in non-diabetic controls
S. M. Gold et al., (43)	T2DM: 23 Control: 23	T2DM: 59.2 ± 8.4 Control: 59.9 ± 8.6	Hippocampus volume (cm <sup>3</sup> ): T2DM - 5.41 ± 0.50 Control - 6.24 ± 0.70	Patients with type 2 diabetes had significantly smaller hippocampal volumes than the control group
Chris Moran et al., (44)	T2DM: 350 No T2DM: 363	T2DM: 67.8 (6.9) No T2DM: 72.1 (7.2)	T2DM hippocampal volume (mL): Right - 2.32 (0.47) Left: 2.22 (0.44) No T2DM hippocampal volume (mL): Right - 2.77 (0.50) Left - 2.61 (0.48)	T2DM was associated with lower total hippocampal volumes
Esther S.C. Korf et al., (45)	T2DM: 202 Control: 204	T2DM: 81.7 ± 5.1 Control: 81.3 ± 4.9	Hippocampal volume (mm <sup>3</sup> ): T2DM - 5,348 ± 805 No Diabetes - 5,406 ± 856	T2DM have a two times increased risk of hippocampal atrophy
Hannah Bruehl et al., (46)	T2DM: 18 Controls: 18	T2DM: 16.46 ± 1.89 Controls : 17.16 ± 1.45	Hippocampus Volume (cc): T2DM - 2.58 ± 0.4 Controls - 2.98 ± 0.33	T2DM had significantly reduced hippocampal volume compared to obese controls
Manon Brundel et al., (47)	T2DM: 56 Control: 30	T2DM: 70.0 ± 5.2 Control: 68.1 ± 4.3	T2DM hippocampal volume (cm <sup>3</sup> ): Left - 3.3 ± 0.4 Right - 3.5 ± 0.4 Control hippocampal volume (cm <sup>3</sup> ): Left - 3.6 ± 0.3 Right - 3.8 ± 0.3	A subtle effect of T2DM was seen with atrophy in the hippocampal region

R. Hemptel al., (48)	T2DM: 40 Control: 47	T2DM: Female- 58.91 ± 9.99 Male - 58.82 ± 7.01 Control: Female- 59.18 ± 7.5 Male- 60.82 ± 8.45	T2DM Hippocampus Volume (cc): Female - 2.48 ± 0.28 Male - 2.84 ± 0.26 Control Hippocampus Volume (cc): Female - 3.02 ± 0.31 Male - 3.09 ± 0.33	There is a gender difference in the association of T2DM and hippocampal volumes. Females with T2DM are likely to suffer more brain complications than males
----------------------	-------------------------	---	---	---

Table 1: T2DM and Hippocampal volume

causing elevated cortisol levels. (36) Blunted cortisol awakening responses in insulin resistance are associated with smaller hippocampal volume. (37) Higher cortisol levels may activate NACHT, LRR, and PYD domain-containing protein 1 (NLRP1) inflammasome in hippocampal neurons, thus promoting neuroinflammation and thereby neuronal injury. (38)

Resting-state functional connectivity MRI for T2DM patients shows reduced hippocampus connectivity towards other brain regions, including the fusiform gyrus, frontal gyrus, temporal gyrus, anterior cingulate gyrus, medial frontal gyrus, posterior cingulate gyrus, precuneus, and inferior parietal lobule. (39)

Memory is the retention, recording, and retrieving of the experience that can be brought into consciousness. Human memory is subdivided into short-term memory and long-term memory. The conversion of short-term memory to long-term memory is defined as memory consolidation. (49) Long-term memory is qualitatively categorized as declarative memory and non-declarative memory (Figure 3). Declarative memory, also referred to as explicit memory, is composed of semantic memory, i.e. memory of fact, and episodic memory, i.e. memory of events. (50) This form of memory is acquired and stored during conscious or explicit learning. (51,52) Non-declarative memory, in contrast, implies the memory which can be recalled without conscious effort and is also termed implicit or procedural memory. (53)

**Memory**

**Long-Term Memory**

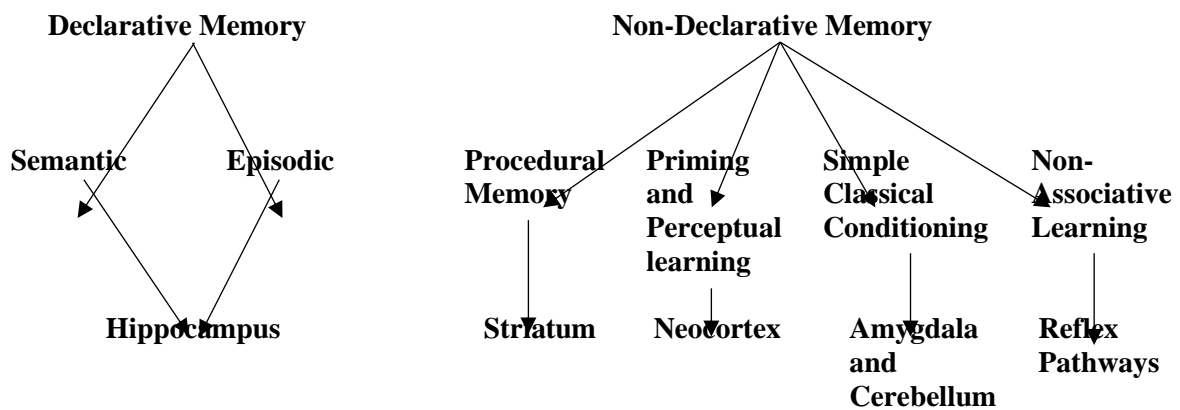


Figure 3: Taxonomy of mammalian memory system (54)

**Hippocampus and Memory**

William Beecher Scoville conducted an experimental brain operation to treat medically intractable epilepsy of Henry Gustave Molaison (H.M.) on August 25, 1953. H.M. bilateral medial temporal lobe resection involves the hippocampus, amygdaloid complex, and entorhinal cortex. H.M. epileptic attack was

reduced though he lived with anterograde amnesia for the rest of his life. H.M. chapter shares an essential lesson about memory. (55) Atrophy to the hippocampus could lead to amnesia. Hippocampus could be affected by several common disparate neurologic disorders, including epilepsy, Alzheimer's disease, cerebrovascular disease, acute ischemic stroke,

transient amnesia and encephalitis. For example, in Alzheimer's disease, the entorhinal cortex is manifested and ultimately spreads to the hippocampus properly. The advanced technique of MRI scans made it easy to rule out hippocampal atrophy in amnesic patients.

When we remember the past events of our life we can generate a precise image of the particular experience, which recreate the feeling of experiencing the moments again. The hippocampus has been known for its established role in storing declarative forms of memory. When we remember the past events of our life we can reorganise a precise image of the particular experience, which recreates the feeling of experiencing the moments again. The hippocampus activation has been linked to integrating and retrieving the past experience of rich vivid episodic memories. (56) Measures of semantic richness and vocabulary depth for previously acquired, highly familiar words were poorly produced among the hippocampal-damaged patients. (57) The hippocampus has been articulated in relating incoming words to each other and stored semantic knowledge during sentence comprehension to build meaning across words. (58) Damaged hippocampus amnesia patients produce autobiographical narratives of past and future events that contain significantly less episodic details compared to healthy participants. (59)

### Conclusion

There is strong evidence that T2DM increase the risk of hippocampal atrophy. Insulin signalling dysregulation, oxidative stress and neuroinflammation are critical factors in hippocampal volume loss. Furthermore, damage hippocampus could trigger declarative memory impairment. Optimal glycaemic control and prophylactic interventions could improve hippocampal atrophy and memory impairment in T2DM.

### Declaration of Conflicting Interests

The authors declared no potential conflict of interest with respect to the research, authorship, and/or publication of this article.

### Funding

The author(s) received no financial support for the research, authorship, and/or publication of this article.

### Acknowledgements

None

### Reference

1. Zheng, Y., Ley, S., & Hu, F. (2017). Global aetiology and epidemiology of type 2 diabetes mellitus and its complications. *Nature Reviews Endocrinology*, 14(2), 88-98. <https://doi.org/10.1038/nrendo.2017.151>
2. Gorska-Ciebiada, M., Saryusz-Wolska, M., Borkowska, A., Ciebiada, M., & Loba, J. (2015). Adiponectin, leptin and IL-1  $\beta$  in elderly diabetic patients with mild cognitive impairment. *Metabolic Brain Disease*, 31(2), 257-266. <https://doi.org/10.1007/s11011-015-9739-0>
3. Cukierman-Yaffe, T. (2009). Relationship Between Baseline Glycemic Control and Cognitive Function in Individuals With Type 2 Diabetes and Other Cardiovascular Risk Factors: The Action to Control Cardiovascular Risk in Diabetes-Memory in Diabetes (ACCORD-MIND) Trial. *Diabetes Care*, 32(8), e103-e103. <https://doi.org/10.2337/dc09-0821>
4. Nguyen, H., Grzywacz, J., Arcury, T., Chapman, C., Kirk, J., & Ip, E. et al. (2010). Linking Glycemic Control and Executive Function in Rural Older Adults with Diabetes Mellitus. *Journal Of The American Geriatrics Society*, 58(6), 1123-1127. <https://doi.org/10.1111/j.1532-5415.2010.02857.x>
5. Albai, O., Frandes, M., Timar, R., Roman, D., & Timar, B. (2019). Risk factors for developing dementia in type 2 diabetes mellitus patients with mild cognitive impairment. *Neuropsychiatric Disease And Treatment*, Volume 15, 167-175. <https://doi.org/10.2147/ndt.s189905>
6. Strachan, M., Reynolds, R., Marioni, R., & Price, J. (2011). Cognitive function, dementia and type 2 diabetes mellitus in the elderly. *Nature Reviews Endocrinology*, 7(2), 108-114. <https://doi.org/10.1038/nrendo.2010.228>
7. Thomassen, J., Tolstrup, J., Benn, M., & Frikke-Schmidt, R. (2020). Type-2 diabetes and risk of dementia: observational and Mendelian randomisation studies in 1 million individuals. *Epidemiology And Psychiatric Sciences*, 29. <https://doi.org/10.1017/s2045796020000347>
8. Biessels, G., & Despa, F. (2018). Cognitive decline and dementia in diabetes mellitus: mechanisms and clinical implications. *Nature*

- Reviews Endocrinology, 14(10), 591-604.  
<https://doi.org/10.1038/s41574-018-0048-7>
9. Janelidze, S., Hertze, J., Nägga, K., Nilsson, K., Nilsson, C., & Wennström, M. et al. (2017). Increased blood-brain barrier permeability is associated with dementia and diabetes but not amyloid pathology or APOE genotype. *Neurobiology Of Aging*, 51, 104-112.  
<https://doi.org/10.1016/j.neurobiolaging.2016.11.017>
10. Sherzai, D., Sherzai, A., Lui, K., Pan, D., Chiou, D., Bazargan, M., & Shaheen, M. (2016). The Association Between Diabetes and Dementia Among Elderly Individuals: A Nationwide Inpatient Sample Analysis. *Journal Of Geriatric Psychiatry And Neurology*, 29(3), 120-125.  
<https://doi.org/10.1177/0891988715627016>
11. Sun, Q., Chen, G., Wang, X., Yu, Y., Hu, Y., & Yan, L. et al. (2018). Alterations of White Matter Integrity and Hippocampal Functional Connectivity in Type 2 Diabetes Without Mild Cognitive Impairment. *Frontiers In Neuroanatomy*, 29(3):120-5.  
<https://doi.org/10.3389/fnana.2018.00021>
12. Milne, N., Bucks, R., Davis, W., Davis, T., Pierson, R., Starkstein, S., & Bruce, D. (2017). Hippocampal atrophy, asymmetry, and cognition in type 2 diabetes mellitus. *Brain And Behavior*, 8(1), e00741.  
<https://doi.org/10.1002/brb3.741>
13. Eichenbaum, H. (2000). A cortical-hippocampal system for declarative memory. *Nature Reviews Neuroscience*, 1(1), 41-50.  
<https://doi.org/10.1038/35036213>
14. Bird, C. (2017). The role of the hippocampus in recognition memory. *Cortex*, 93, 155-165.  
<https://doi.org/10.1016/j.cortex.2017.05.016>
15. Butterfield, D., Di Domenico, F., & Barone, E. (2014). Elevated risk of type 2 diabetes for development of Alzheimer disease: A key role for oxidative stress in brain. *Biochimica Et Biophysica Acta (BBA) - Molecular Basis Of Disease*, 1842(9), 1693-1706.  
<https://doi.org/10.1016/j.bbadis.2014.06.010>
16. Eichenbaum, H. (2014). Time cells in the hippocampus: a new dimension for mapping memories. *Nature Reviews Neuroscience*, 15(11), 732-744.  
<https://doi.org/10.1038/nrn3827>
17. Howard, M., & Eichenbaum, H. (2015). Time and space in the hippocampus. *Brain Research*, 1621, 345-354.  
<https://doi.org/10.1016/j.brainres.2014.10.069>
18. Kesner, R., & Rolls, E. (2015). A computational theory of hippocampal function, and tests of the theory: New developments. *Neuroscience & Biobehavioral Reviews*, 48, 92-147.  
<https://doi.org/10.1016/j.neubiorev.2014.11.009>
19. Farias Serratos F, Farias Serratos BM, Farias Serratos CV, Santana Ramirez A, Kawai K. (2017). Temporal Lobe Epilepsy and Hippocampal Sclerosis: Historical Review. *Hospital Medicine and Clinical Management*. 2017;10(3):108-14.
20. Andersen P, Morris R, Amaral D, Bliss T, O'Keefe J. (2006). *The hippocampus book*. Oxford university press.
21. H.M. Duvernoy. (2005). *The Human Hippocampus: Functional Anatomy, Vascularization and Serial Sections with MRI*, 3rd edition. *AJNR: American Journal of Neuroradiology*, 26(10), 2702.  
[https://doi.org/10.1016/s0150-9861\(05\)83157-8](https://doi.org/10.1016/s0150-9861(05)83157-8)
22. Iniesta, I. (2014). On the origin of Ammon's horn. *Neurología (English Edition)*, 29(8), 490-496.  
<https://doi.org/10.1016/j.nrleng.2012.03.024>
23. Dudek, S., Alexander, G., & Farris, S. (2016). Rediscovering area CA2: unique properties and functions. *Nature Reviews Neuroscience*, 17(2), 89-102.  
<https://doi.org/10.1038/nrn.2015.22>
24. McCrimmon, R., Ryan, C., & Frier, B. (2012). Diabetes and cognitive dysfunction. *The Lancet*, 379(9833), 2291-2299.  
[https://doi.org/10.1016/s0140-6736\(12\)60360-2](https://doi.org/10.1016/s0140-6736(12)60360-2)
25. Rasgon, N., Kenna, H., Wroolie, T., Kelley, R., Silverman, D., & Brooks, J. et al. (2011). Insulin resistance and hippocampal volume in women at risk for Alzheimer's disease. *Neurobiology Of Aging*, 32(11), 1942-1948.  
<https://doi.org/10.1016/j.neurobiolaging.2009.12.005>
26. Talbot, K. and Wang, H., 2014. The nature, significance, and glucagon-like peptide-1 analog treatment of brain insulin resistance in Alzheimer's disease. *Alzheimer's & Dementia*, 10(1S).  
<https://doi.org/10.1016/j.jalz.2013.12.007>
27. Wisse, L., de Bresser, J., Geerlings, M., Reijmer, Y., Portegies, M., & Brundel, M. et al. (2014). Global brain atrophy but not hippocampal atrophy is related to type 2 diabetes. *Journal Of The Neurological*

- Sciences, 344(1-2), 32-36. <https://doi.org/10.1016/j.jns.2014.06.008>
28. Verdile, G., Fuller, S., & Martins, R. (2015). The role of type 2 diabetes in neurodegeneration. *Neurobiology Of Disease*, 84, 22-38. <https://doi.org/10.1016/j.nbd.2015.04.008>
29. Maritim, A., Sanders, R., & Watkins, J. (2003). Diabetes, oxidative stress, and antioxidants: A review. *Journal Of Biochemical And Molecular Toxicology*, 17(1), 24-38. <https://doi.org/10.1002/jbt.10058>
30. Asmat, U., Abad, K., & Ismail, K. (2016). Diabetes mellitus and oxidative stress—A concise review. *Saudi Pharmaceutical Journal*, 24(5), 547-553. <https://doi.org/10.1016/j.jsps.2015.03.013>
31. Butterfield, D. (2006). Oxidative Stress in Neurodegenerative Disorders. *Antioxidants & Redox Signaling*, 8(11-12), 1971-1973. <https://doi.org/10.1089/ars.2006.8.1971>
32. Duarte, J., Pereira, J., Quendera, B., Raimundo, M., Moreno, C., & Gomes, L. et al. (2015). Early Disrupted Neurovascular Coupling and Changed Event Level Hemodynamic Response Function in Type 2 Diabetes: An fMRI Study. *Journal Of Cerebral Blood Flow & Metabolism*, 35(10), 1671-1680. <https://doi.org/10.1038/jcbfm.2015.106>
33. Kooistra, M., Geerlings, M., Mali, W., Vincken, K., van der Graaf, Y., & Biessels, G. (2013). Diabetes mellitus and progression of vascular brain lesions and brain atrophy in patients with symptomatic atherosclerotic disease. The SMART-MR study. *Journal Of The Neurological Sciences*, 332(1-2), 69-74. <https://doi.org/10.1016/j.jns.2013.06.019>
34. Debette, S., Seshadri, S., Beiser, A., Au, R., Himali, J., & Palumbo, C. et al. (2011). Midlife vascular risk factor exposure accelerates structural brain aging and cognitive decline. *Neurology*, 77(5), 461-468. <https://doi.org/10.1212/WNL.0b013e318227b227>
35. Hirunpattarasilp, C., Attwell, D., & Freitas, F. (2019). The role of pericytes in brain disorders: from the periphery to the brain. *Journal Of Neurochemistry*, 150(6), 648-665. <https://doi.org/10.1111/jnc.14725>
36. Stranahan, A., Arumugam, T., Cutler, R., Lee, K., Egan, J., & Mattson, M. (2008). Diabetes impairs hippocampal function through glucocorticoid-mediated effects on new and mature neurons. *Nature Neuroscience*, 11(3), 309-317. <https://doi.org/10.1038/nn2055>
37. Ursache, A., Wedin, W., Tirsi, A., & Convit, A. (2012). Preliminary evidence for obesity and elevations in fasting insulin mediating associations between cortisol awakening response and hippocampal volumes and frontal atrophy. *Psychoneuroendocrinology*, 37(8), 1270-1276. <https://doi.org/10.1016/j.psyneuen.2011.12.020>
38. Zhang, B., Zhang, Y., Wu, W., Xu, T., Yin, Y., & Zhang, J. et al. (2017). Chronic glucocorticoid exposure activates BK-NLRP1 signal involving in hippocampal neuron damage. *Journal Of Neuroinflammation*, 14(1). <https://doi.org/10.1186/s12974-017-0911-9>
39. Zhou, H., Lu, W., Shi, Y., Bai, F., Chang, J., & Yuan, Y. et al. (2010). Impairments in cognition and resting-state connectivity of the hippocampus in elderly subjects with type 2 diabetes. *Neuroscience Letters*, 473(1), 5-10. <https://doi.org/10.1016/j.neulet.2009.12.057>
40. Van Bussel, F., Backes, W., Hofman, P., van Boxtel, M., Schram, M., & Stehouwer, C. et al. (2016). Altered Hippocampal White Matter Connectivity in Type 2 Diabetes Mellitus and Memory Decrements. *Journal Of Neuroendocrinology*, 28(3). <https://doi.org/10.1111/jne.12366>
41. Zhang, Y., Zhang, J., Liu, C., Wei, P., Zhang, X., & Yuan, Q. et al. (2015). Memory Dysfunction in Type 2 Diabetes Mellitus Correlates with Reduced Hippocampal CA1 and Subiculum Volumes. *Chinese Medical Journal*, 128(4), 465-471. <https://doi.org/10.4103/0366-6999.151082>
42. Hayashi, K., Kurioka, S., Yamaguchi, T., Morita, M., Kanazawa, I., & Takase, H. et al. (2011). Association of cognitive dysfunction with hippocampal atrophy in elderly Japanese people with type 2 diabetes. *Diabetes Research And Clinical Practice*, 94(2), 180-185. <https://doi.org/10.1016/j.diabres.2011.07.002>
43. Gold, S., Dziobek, I., Sweat, V., Tirsi, A., Rogers, K., & Bruhl, H. et al. (2007). Hippocampal damage and memory impairments as possible early brain complications of type 2 diabetes. *Diabetologia*, 50(4), 711-719. <https://doi.org/10.1007/s00125-007-0602-7>
44. Moran, C., Phan, T., Chen, J., Blizzard, L., Beare, R., & Venn, A. et al. (2013). Brain Atrophy in Type 2 Diabetes. *Diabetes Care*, 36(12), 4036-4042. <https://doi.org/10.2337/dc13-0143>



45. Korf, E., White, L., Scheltens, P., & Launer, L. (2006). Brain Aging in Very Old Men With Type 2 Diabetes. *Diabetes Care*, 29(10), 2268-2274. <https://doi.org/10.2337/dc06-0243>
46. Bruehl, H., Sweat, V., Tirsi, A., Shah, B., & Convit, A. (2011). Obese Adolescents with Type 2 Diabetes Mellitus Have Hippocampal and Frontal Lobe Volume Reductions. *Neuroscience And Medicine*, 02(01), 34-42. <https://doi.org/10.4236/nm.2011.21005>
47. Brundel, M., van den Heuvel, M., de Bresser J., Kappelle, L., & Biessels, G. (2010). Cerebral cortical thickness in patients with type 2 diabetes. *Journal Of The Neurological Sciences*, 299(1-2), 126-130. <https://doi.org/10.1016/j.jns.2010.08.048>
48. Hempel, R., Onopa, R., & Convit, A. (2012). Type 2 diabetes affects hippocampus volume differentially in men and women. *Diabetes/Metabolism Research And Reviews*, 28(1), 76-83. <https://doi.org/10.1002/dmrr.1230>
49. McGaugh, J. (1966). Time-Dependent Processes in Memory Storage. *Science*, 153(3742), 1351-1358. <https://doi.org/10.1126/science.153.3742.1351>
50. Tulving E. (1972). Episodic and Semantic Memory. In E. Tulving, & W. Donaldson (Eds.), *Organization of Memory* (pp. 381-403). Cambridge, MA: Academic Press.
51. Lezak, M. D., Howieson, D. B., & Loring, D. W. (2004). *Neuropsychological Assessment* (4th ed.). New York: Oxford University Press.
52. Squire, L. R. (1987). *Memory and brain*. Oxford University Press.
53. Roediger, H. (1990). Implicit memory: Retention without remembering. *American Psychologist*, 45(9), 1043-1056. <https://doi.org/10.1037/0003-066x.45.9.1043>
54. Manns, J., & Squire, L. (2001). Perceptual learning, awareness, and the hippocampus. *Hippocampus*, 11(6), 776-782. <https://doi.org/10.1002/hipo.1093>
55. Scoville, W., & Milner, B. (1957). Loss Of Recent Memory After Bilateral Hippocampal Lesions. *Journal Of Neurology, Neurosurgery & Psychiatry*, 20(1), 11-21. <https://doi.org/10.1136/jnnp.20.1.11>
56. St-Laurent, M., Moscovitch, M., Jadd, R., & McAndrews, M. (2014). The perceptual richness of complex memory episodes is compromised by medial temporal lobe damage. *Hippocampus*, 24(5), 560-576. <https://doi.org/10.1002/hipo.22249>
57. Klooster, N., & Duff, M. (2015). Remote semantic memory is impoverished in hippocampal amnesia. *Neuropsychologia*, 79, 42-52. <https://doi.org/10.1016/j.neuropsychologia.2015.10.017>
58. Piai, V., Anderson, K., Lin, J., Dewar, C., Parvizi, J., Dronkers, N., & Knight, R. (2016). Direct brain recordings reveal hippocampal rhythm underpinnings of language processing. *Proceedings Of The National Academy Of Sciences*, 113(40), 11366-11371. <https://doi.org/10.1073/pnas.1603312113>
59. Kurczek, J., Wechsler, E., Ahuja, S., Jensen, U., Cohen, N., Tranel, D., & Duff, M. (2015). Differential contributions of hippocampus and medial prefrontal cortex to self-projection and self-referential processing. *Neuropsychologia*, 73, 116-126. <https://doi.org/10.1016/j.neuropsychologia.2015.05.002>