

EPIDEMIOLOGICAL AND CLINICAL, PATHOLOGICAL STUDY OF SUPERIOR VENA CAVA SYNDROME CASES IN RADIOTHERAPY-ONCOLOGY WARD OF TABRIZ UNIVERSITY OF MEDICAL SCIENCES

¹Mohammad Reza Ghaffary, ²Ali Reza Naseri, ³Shamsi Ghaffari

¹Associate Professor of Tuberculosis and Lung Disease Research Center, Tabriz University of Medical Sciences, Tabriz, Iran, Email: Mohammadrezaghaffary@gmail.com

²Associate Professor of radio-oncology, Medical Faculty, Tabriz University, Tabriz, Iran, Email: Naseri47@gmail.com

³Associate Professor of Pediatric Cardiology, Medical Faculty, Tabriz University, Tabriz, Iran, Email: Shamsi.ghaffari@gmail.com

Abstract

Background: Superior vena cava syndrome refers to an obstruction in the superior vena cava pathway that dyspnea, facial edema, chest pain and distension of cervical and chest veins are the most common sign and symptoms of this syndrome. The present study investigates the epidemiological, clinical and pathological characteristics of the superior vena cava syndrome in the radiotherapy-oncology ward of Imam Khomeini educational center between 2003 and 2011.

Methods: The present study is a descriptive cross-sectional study conducted retrospectively. Data including demographic information, epidemiological information, early signs and symptoms, diagnostic methods and underlying pathology were collected through a checklist of archived medical records related to the radiotherapy ward of Imam Khomeini Educational Center between 2003 and 2011. All of these patients were referred to the ward with a diagnosis of superior vena cava syndrome. The frequency of causes and contribution of each of them in the development of superior vena cava syndrome were examined in SPSS-16 software.

Results: Out of 180 patients with superior vena cava syndrome, 125 were male (69.5%) and 55 were female (30.5%). The mean age of patients with this syndrome was 52.3 +18.3 years. The mean age of males was 51.76 years and the mean age of females was 54.8 years. Majority of the patients were diagnosed with bronchoscopy based on superior vena cava syndrome, and a small number of them were diagnosed based on biopsy under CT scan and chest x-ray. In general, superior vena cava syndrome was confirmed by combining clinical symptoms and para-clinical findings. The underlying disease causing superior vena cava syndrome was lung cancers in 67.74%, lymphoma cases in 22.58%, other malignancies in 3.22%, and the pathology of the disease was not identified in 6.45% of cases. Regarding the underlying pathology of lung cancer, 38.09% of cases were small cell lung cancer, 47.61% were squamous cell carcinoma and 14.28% were adenocarcinoma.

Conclusions: Most of the findings of this study, except for two cases, were consistent with the findings of other studies. These two cases were related to the rate of lymphoma and squamous cell carcinoma, which were higher than other studies.

Keywords: Superior vena cava syndrome, Malignancies, Bronchoscopy.

INTRODUCTION

The first pathological description of superior vena cava obstruction was made in 1757 in a patient with syphilitic aortic aneurysm. In patients with this syndrome, signs such as dyspnea, facial edema, chest pain and distension of cervical and chest veins were observed. It is now defined as an obstruction in the superior vena cava, which causes specific symptoms of the disease, such as facial edema, distension of cervical and chest veins, dyspnea, and coughing. The etiology of this syndrome is mainly lung cancer, lymphoma and other malignancies. This syndrome is one of the medical emergencies sometimes seen in patients with malignancies that need immediate treatment [1-4]. In 1954, Schechter reported 274 cases of superior vena cava syndrome. In 40% of these patients, the superior vena cava syndrome was caused by syphilitic aneurysm or tuberculous mediastinitis. These cases have been eliminated and now in almost 70% of cases, lung cancer is the cause of superior vena cava syndrome [1, 2].

The superior vena cava is the largest artery that drains blood vessels from the head, neck, upper limbs, and upper chest. This vein is located in the middle mediastinum and is surrounded by strong structures such as the sternum, trachea, right main bronchus, aorta, pulmonary arteries, and lymph nodes. The superior vena cava stretches from the junction of the right and left brachiocephalic veins to the right atrium at a distance of about 6-8 cm. The end 2 cm of the superior vena cava is located inside the pericardial cavity and is partially connected to the pericardial fold. The superior vena cava is formed at the border of the first right rib cartilage of the right and left brachiocephalic veins. After that brachiocephalic vein was formed, it passes an approximately horizontal path with a length of 6 to 7 cm long behind the first right rib cartilage and joins the right brachiocephalic vein, which has a vertical path, and forms the superior vena cava [1-4]. The aim of present study was to evaluate the

frequency of epidemiological factors involved in superior vena cava syndrome such as the frequency of signs and symptoms, the etiological factors involved and the survival rate of patients with superior vena cava syndrome [5, 6]. In addition, given the regional prevalence of lymphoma, it is hypothesized that lymphoma has the highest prevalence in the primary pathology of the superior vena cava syndrome?

METHODS

The present study is a descriptive cross-sectional and retrospective study conducted based on the available samples and information in the medical records of patients referred to the radiotherapy-oncology ward of Imam Khomeini Educational Center from 2003 to 2011. The medical records of the patients who were referred to this center with the diagnosis of superior vena cava syndrome were obtained and the checklist was completed according to the research form of the cases of superior vena cava syndrome. Epidemiological information, information about the initial signs and symptoms of the disease, and the method of diagnosis and pathology of the underlying disease and the number of radiotherapy sessions was obtained from each patient's medical record and information about the survival of patients with this syndrome was obtained through corresponding or via phone. Due to the unavailability of the address or telephone number in the medical records of these patients, it was not done completely. In this study, a total number of 180 patients with superior vena cava syndrome were referred to this center for radiotherapy. The results of the study were analyzed discussed using SPSS statistical software and descriptive statistical methods.

RESULTS

Out of a total number of 180 patients with superior vena cava syndrome, 125 were male (69.5%) and 55 were female (30.5%). The mean age of patients with this syndrome was 52.3 +18.3 years. The mean age of males was 51.76 years and the mean age of females was 54.8 years. The clinical signs of patients with this syndrome when they referred in order of prevalence included dyspnea, feeling of pressure in head, facial edema, cough, arm edema, chest pain and dysphagia, and symptoms of patients with superior vena cava syndrome at the time of referral in order of prevalence were distension of cervical veins, facial edema, distension of cervical veins, edema of the arms and cyanosis. Majority of the patients were diagnosed with bronchoscopy based on superior vena cava syndrome, and a small number of them were diagnosed based on biopsy under CT scan and chest x-ray (Figure 1). In general, superior vena cava syndrome was confirmed by combining clinical symptoms and para-clinical findings. Out of 180 patients, 155 had pathology reports in the medical records. The pathology diagnosis of the underlying disease was as follows: lung cancer=105 patients (67.74%), lymphoma= 35 patients (22.58%), acute lymphoblastic leukemia type L2= 5, and pathology of 10 patients was not diagnosed (Figure 2). Out of 105 patients with superior vena cava syndrome whose underlying cause was lung cancer, 40 had small cell carcinoma, 50 had squamous cell carcinoma and 15 had adenocarcinoma (Figure 3).

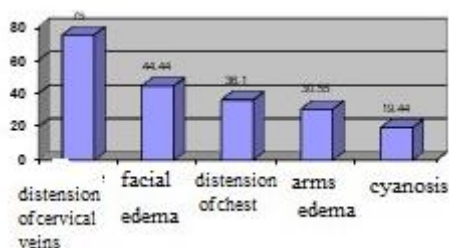


Figure 1. Bar chart of the frequency of symptoms in patients with superior vena cava syndrome.

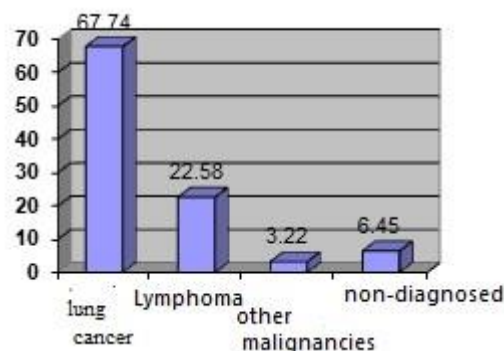


Figure 2. Histogram related to the pathological diagnosis of the primary disease causing the superior vena cava syndrome.

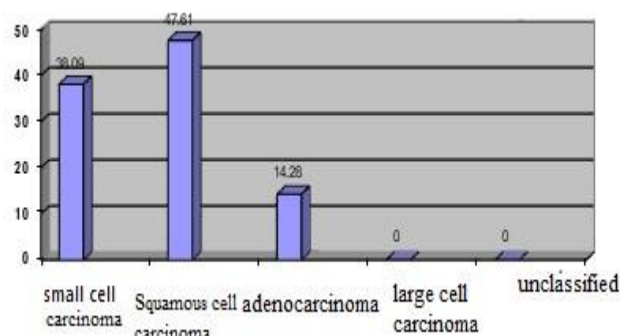


Figure 3. Histogram of subgroups of lung cancer in 21 patients with superior vena cava syndrome.

DISCUSSION

In examining the causes of superior vena cava syndrome, malignant causes are the most common cause of this syndrome. Among the various studies conducted in 78 to 86% of cases, malignant causes were the etiology of the disease.

The following table shows the initial pathological diagnoses of superior vena cava syndrome in 415 patients with this syndrome, collected by several groups (Table 1).

Table 1. Pathological diagnoses of superior vena cava syndrome.

Tissue diagnosis	Bellel	Schraurnagel	Parishetal	Yellinetal	Total
Lung cancer	129(81%)	67(63%)	45(52%)	30(48%)	271(65%)
Lymphoma	129(2%)	10(9%)	8(9%)	13(21%)	43(8%)
Other malignancies (Primary or monastic)	4(3%)	14(13%)	14(16%)	8(13%)	40(10%)
Non-neoplastic	2(1%)	16(15%)	19(22%)	11(18%)	50(12%)
Not diagnosed	21(13%)	-	-	-	21(5%)
Total	159	107	86	63	415

In a study conducted by Armstrong et al. on 4,100 patients with bronchogenic carcinoma who were treated, 99 patients with superior vena cava syndrome were found (2.4%) [7]. Salsali and Cliffon were also found among 4,960 patients with lung cancer, 4.2% of the cases caused the superior vena cava syndrome. In these studies, 80% of the tumors that caused the superior vena cava syndrome were located in the right lung, small cell carcinoma was the most common cause of this syndrome, and this tumor was found in 38% of patients whose lung cancer caused superior vena cava syndrome. In the mentioned study, squamous cell carcinoma was the second most common cause of Superior vena cava syndrome and was the causative agent in 26% of patients with superior vena cava syndrome [8]. In another study conducted by Perez-Soler, among 915 patients with non-Hodgkin's lymphoma treated at Anderson Cancer Center, 36 (about 4%) patients with superior vena cava syndrome were found. Out of the 36 patients, 23 (64%) had large cell lymphoma. Twelve (33%) patients had lymphocytic lymphoma and one patient had large cell follicular lymphoma. Also, among patients with diffuse large cell lymphoma and lymphoblastic lymphoma, 7% and 21%, respectively, had superior vena cava syndrome. Superior vena cava syndrome was seen in 37% of patients with B-cell lymphoma who had sclerosis [9].

Hodgkin's lymphoma generally involves the mediastinum but rarely causes the superior

vena cava syndrome. Other primary mediastinum tumors that cause the superior vena cava syndrome include thymoma and germ cell tumors [9]. Breast cancer is also the most common metastatic disease that causes superior vena cava syndrome. In one study, breast cancer was the cause of superior vena cava syndrome in 11% of cases [10]. Based on previous reports, non-malignant causes of superior vena cava syndrome are not rare and benign causes are nowadays increasing, because intravenous cannulation has increased. Information collected from all hospitals showed that benign causes accounted for more than 22% of cases with superior vena cava syndrome. Superior vena cava obstruction is rare in children, but its causative agents and etiology are numerous in this age group. The causative agents are mainly iatrogenic, which occur mainly after corrective surgery for congenital heart diseases and atrial ventricular shunting in hydrocephalus and catheterization in the superior vena cava for intravenous feeding [10, 11].

In a report of 175 patients with superior vena cava syndrome, 70% of cases were iatrogenic and out of the remaining 53 cases, 37 (70%) were due to mediastinal tumors, 8 (15%) were due to benign granuloma, and 4 (7.5%) were due to congenital anomalies of the cardiovascular system. Among 16 children with superior vena cava syndrome diagnosed at St.jude Hospital, 8 had Hodgkin's lymphoma, 4 had acute lymphoblastic leukemia, 2 had

Hodgkin's disease, 1 had neuroblastoma, and 1 had a yolk sac tumor [2, 8, 12]. One of the very rare causes of superior vena cava syndrome is intrathoracic goiter. In a study carried out between 1984 and 1997 on 4985 patients with goiter, 28 patients (0.6%) had intrathoracic goiter and among 28 patients, symptoms of superior vena cava syndrome were observed only in one case (0.002%) [13]. Painless aortic dissection, which occurs long after aortic valve replacement, can also manifest as superior vena cava syndrome and might be a very rare cause of superior vena cava syndrome [14].

A review of the clinical symptoms of patients with superior vena cava syndrome suggests that dyspnea is the most common symptom of the disease and it is seen in about 63% of patients with superior vena cava syndrome, and feeling of pressure in the head and facial edema are seen in 50% of patients. Other complaints include cough (in 24% of cases), arm edema (in 18% of cases), chest pain (in 15% of cases), and dysphagia (in 9% of cases). Regarding the general symptoms of patients with superior vena cava syndrome, dyspnea is 63%, facial edema and feeling of pressure in the head is 50%, cough is 24%, arm edema is 18%, chest pain is 15%, and dysphagia is 9%. Findings seen during clinical examination in patients with superior vena cava syndrome include distension of cervical veins (in 96% of cases), distension of chest wall (in 54% of cases), facial edema (in 46% of cases), flushing in face (in 19% of cases) and cyanosis. These signs and symptoms may get worse with bending over. Clinical findings in 370 patients with superior vena cava syndrome showed distension of cervical veins in 66% of cases, distension of chest wall in 54% of cases, facial edema in 46% of cases, cyanosis in 20% of cases, flushing in face in 19% of cases, and arm edema in 14% of cases [10, 15].

CONCLUSIONS

The epidemiological information obtained from this study is in line with the information presented in reference books and articles, and 69.5% of patients are males and 30.5% of

patients are females [1, 3, 16]. The mean age of patients with this syndrome was about 52 years and 8 months, which is justified by the fact that the prevalence of malignant diseases is higher at older ages [4, 5, 9]. If the mean age of patients with benign superior vena cava syndrome was mentioned in this mean, we would expect to have a smaller mean age, but since the primary disease of all patients is malignancies and the prevalence of malignancies is more in higher decades, the mean age of 52 years and 8 months is not significantly different from other studies.

Regarding the symptoms of patients with superior vena cava syndrome, most of the symptoms were dyspnea (69.44%), facial edema and feeling of pressure in the head (in 44.44%), cough (36.11%), arm edema (30.55%), chest pain (30.55%) and dysphagia (2.77%). The percentage of these symptoms is almost consistent with the statistics presented in various studies [9]. Symptoms that were present in patients with superior vena cava syndrome were distension of cervical veins (75%), facial edema (44.44%), distension of chest wall (36.1%), arm edema (30.55), and cyanosis (19.44%), respectively. It is also almost similar to the statistics presented in other studies.

Regarding the pathology of the underlying disease, lung cancer accounted for 67.74% of cases, which is almost similar to the statistics of other studies. Lymphoma accounts for 22.58% of cases, which is more than the statistics of other studies. It may be due to higher prevalence of lymphoma in this region. Other malignancies accounted for 3.22% of cases and undiagnosed causes accounted for 6.45% of cases. Among the causes of lung cancer, 38.09% of cases are small cell lung cancer and 14.28% of cases are adenocarcinoma, which is completely consistent with other statistics presented. However, squamous cell carcinoma in this study accounted for 47.61% of lung cancer pathologies, which is much higher than the statistics of other studies. Further studies are needed to justify.

Declarations

Ethics approval and consent to participate: Not applicable.

Consent for publication: Not applicable.

Availability of data and materials: The data related to the results of this study are available upon request from the corresponding author.

Competing interests: The authors declare that they have no competing interests

Funding: Not applicable.

Acknowledgements: Not applicable.

References

- [1] Vincent J, DeVita T, Hellman S, Rosenberg SA. *Cancer: Principles and Practice of Oncology*. 5th ed. Lippincott Williams & Wilkins; 1999.
- [2] Prez C, Luther W. *Principales and practice of radiation oncology*. 3th ed. Lippincott Williams & Wilkins; 1998.
- [3] Gray H. *Gray's Anatomy*. Running Press, U. S.; 1987.
- [4] Schindler N, Vogelzang R. Superior vena cava syndrome: Experience with endovascular stents and surgical therapy. *Surg Clin North Am*. 1999;79:683-94.
- [5] Ha
- [6] Alharbi AS, Alhayan MS, Alnami SK, Traad RS, Aldawsari MA, Alharbi SA, Sharif AO, Alboqami ST, Alshammari SA, Alzeer MK, Alshammari MA. Epidemiology and Risk Factors of Stroke. *Arch. Pharm. Pract*. 2019;10(4):60-6
- [7] Armstrong BA, Perez CA, Simpson JR, Hederman MA. Role of irradiation in the management of superior vena cava syndrome. *Int J Radiat Oncol Biol Phys*. 1987;13(4):531-39.
- [8] Salsali M, Clifton EE. Superior vena caval obstruction in carcinoma of lung. *N Y State J Med*. 1969;69:2875-80.
- [9] Perez-Soler R, McLaughlin P, Velasquez WS, Hagemester FB, Zornoza J, Manning JT, Fuller LM, Cabanillas F. Clinical features and results of management of superior vena cava syndrome secondary to lymphoma. *J Clin Oncol*. 1984;2:260.
- [10] Wilson LD, Detterbeck FC, Yahalom J. Clinical practice. Superior vena cava syndrome with malignant causes. *N Engl J Med*. 2007;356(18):1862-69.
- [11] Thony FMD, Witmeyer P, Angiolini S, Brambilla C, Coulomb M, Ferretti G. Endovascular treatment of superior vena cava obstruction in patients with malignancies. *Eur Radiol*. 1999;9(5):965-71.
- [12] Spencer RA, Ammar S. Superior Vena Cava Syndrome, 2007. <http://www.med.ucla.edu/modules/wfsection/article.php?articleid=319>. Accessed 10 Jan 2018
- [13] Cengiz K, Aykin A, Demirci A, Diren B. Intrathoracic goiter with hyperthyroidism, tracheal compression, superior vena cava syndrome, and Horner's syndrome. *Chest*. 1990;97(4):1005-6.
- [14] Hayashi Y, Ohtake S, Sawa Y, Imagawa H, Hirata N, Matsuda H. Painless aortic dissection late after aortic valve replacement, presenting as superior vena cava syndrome. *J Thorac Cardiovasc Surg*. 1998;46(8):724-29.
- [15] Laguna Del Estal PGNT, Murillas Angoitti J, Martín Alvarez H, Portero Navío JL, Moya Mir M. "Superior vena cava syndrome: a study based on 81 cases. *Anales de Medicina Interna*, 1998;15(9):470-75.
- [16] Qanadli SDEHM, Bruckert F, Judet O, Barré O, Chagnon S, Lacombe P. Helical CT phlebography of the superior vena cava: diagnosis and evaluation of venous obstruction. *Am J Roentgenol*. 1999;172(5):1327-33