

EFFICACY OF TOPICAL TACROLIMUS 0.05% SUSPENSION IN STEROID-RESISTANT AND STEROID- DEPENDENT VERNAL KERATOCONJUNCTIVITIS: A CASE SERIES AND REVIEW OF LITRETURES

¹Mitra Akbari

¹M.D., Associate Professor of Ophthalmology, Cornea, and Anterior Segment Eye Research Center, Eye Department, School of Medicine, Guilan University of Medical Sciences, Rasht, Iran, mitra.akbari20@gmail.com

Abstract

Objective: The purpose of this study was to investigate the safety and effectiveness of topical tacrolimus 0.05% suspension in the management of prolonged steroid-dependent and -resistant vernal keratoconjunctivitis (VKC).

Materials and methods: The present interventional prospective case series were conducted on the research units suffering from refractory VKC between 2017, April and 2020, December. Despite routine drug treatment, consisting of topical steroids (steroid-resistant group), all subjects exhibited active symptomatic illness or were dependent on topical steroids (steroid-dependent group). After discontinuation of all medications for at least 1 week, the patients received eye drop (topical tacrolimus 0.05%) minimally for six months. Objective and subjective signs and symptoms were examined for alterations after one week, and one and six months of treatment. Analyses were continued for probable systemic and ocular adverse effects.

Results: The study included 28 eyes of 14 participants (including 4 females and 10 males), with the mean age of 22 ± 8 years (between 11 and 38 years), and the mean VKC duration of 12 ± 6 years (between 5 and 23 years), as well as follow up period of 10 ± 2 months (between 6 and 12 months). The results showed an improvement ($P < 0.001$) in the symptoms such as mucus discharge, foreign body sensation, photosensitivity, redness, burning and itching. The initial sign was conjunctival hyperemia, which improved one week after treatment. Other objective signs including, conjunctival and limbal papillary hypertrophy, corneal pannus and corneal punctate epithelial erosions improved at least one month after treatment. No changes were observed in corneal opacity during follow-up ($p > 0.05$). There were no systemic or ocular adverse effects.

Conclusion: This is the first time that tacrolimus suspension drops 0.05%, are used in these cases. Topical tacrolimus 0.05% was shown to be an effectiveness and safe agent to treat the refractory VKC. This drug is recommended to be prescribed prior to the appearance of side effects such as corneal opacity, irreversible deficiency in limbal stem cell, and steroid side effects.

Keywords: Vernal keratoconjunctivitis, Tacrolimus eye drop, Refractory.

INTRODUCTION

Vernal keratoconjunctivitis (VKC) as an ocular allergic disease in children has specifications such as chronic and acute cornea and conjunctival inflammations probably resulting in visual impairment (1). The disease mostly occurs among children and adults who are in warm climatic conditions. About 50% of affected subjects simultaneously suffer from other allergic complications. The disease depends on the season, usually from early spring to autumn. The perennial cases that are likely to continue for the entire year, particularly those who are living in a climate of subtropical or desert, are not uncommon (2,3). Existing therapeutic medications for VKC treatment are immunomodulators, corticosteroids, mast-cell stabilizers and antihistamines. A majority of patients with VKC needs prolonged therapeutic measures. Moderate to severe types of VKC can be treated mainly with topical steroids, but not for a long time (3, 4). Recently, topical immunomodulatory medications including cyclosporine and tacrolimus (TAC) eye drops have been used for its treatment (5-10). Furthermore, steroid dependency is a frequent finding in these patients, who make them prone to steroid-induced complications including cataract, glaucoma especially in children aged less than 10 years, and infectious diseases. These complications may contribute to severe visual impairment in these young individuals (11,12). Therefore, finding the ways including high potency steroid sparing medications, which subside their chronic inflammation and decrease their dependency to steroids might potentially reduce their visual impairment and drug-induced complications (13-15).

The calcineurin-inhibitor of TAC impedes the activation of T-lymphocytes, with a prophylactic effect for organ rejection in patients with transplant surgery (16,17). The topical TAC as a strong immunosuppressant is extensively prescribed to inhibit transplant rejection of organs like kidney and liver. Topical TAC 0.03% is reportedly potent agent to manage the giant papillary conjunctivitis and VKC (18-20). The topical TAC preparations and cyclosporin ophthalmic solution have been

recently documented to be effective in the VKC therapy. These two medications belong to calcineurin inhibitors capable of deactivating the T cells and relevant produced cytokines contributing to develop the VKC. The inhibitory activity of cyclosporin on the T cells is approximately 100 times less than that of TAC, thus the preparation of ophthalmic TAC can be stronger against the severe form of VKC (21-25). The present research aimed to investigate the safety and effectiveness of TAC suspension 0.05% on treatment of long standing refractory VKC patients.

Materials and methods

The patients with severe refractory VKC who received topical TAC enrolled consecutively in this prospective interventional case series with minimally six-month follow-up period. They admitted to Amiralmomenin Ophthalmology Center from April 2017 to December 2020. Our protocol was implemented in accordance with the Declaration of Helsinki, and approved by the ethics committee of the Center for Ophthalmic Research at Guilan University of Medical Sciences (Rasht, Iran). After completely explaining the study objectives and methodology to all patients at the baseline, they signed an informed written consent before the interventions.

Patient's selection

Refractory VKC was categorized into two groups; steroid-resistant and steroid-dependent groups. Steroid resistant VKC was defined as cases unresponsive to topical steroids (at least two weeks topical steroids every 6 hours). Cases who also needed to at least 1-month steroid usage to control symptoms and signs were also included (steroid dependent group). Exclusion criteria were sub-conjunctival injection or systemic consumption of corticosteroids and/or systemic or ophthalmic consumption of immune-suppressants for two weeks before starting the project, receiving immune modulation treatment or desensitization, a history of eye infections, diabetes, waiting for baby, breastfeeding, or planning for pregnancy within the study period,

drug allergy, a history of pancreatic, hepatic, renal or cardiac problems (26, 27).

Scoring signs and symptoms

The severity of symptoms and signs were evaluated at the baseline, and one week, and one and six months after intervention. The severity of subjective symptoms (including mucus discharge, photophobia, foreign body sensation, redness, burning and itching) was assessed on the basis of a four-grade scale, indicating a grading scale of 0 as no symptoms, 1 as mild occasional symptom, 2 as moderate

(frequent) symptoms, and 3 or severe (constant) symptoms. The assessed objective signs for severity were corneal involvement, limbus, and palpebral and bulbar conjunctiva. The evaluation of corneal pannus and corneal opacity, bulbar conjunctival hyperemia, limbal papillary hypertrophy (including Horner-Trantas' dots), tarsal papillary hypertrophy, punctate epithelial erosion and keratitis was performed in accordance with four-grade scale, indicating 0 as normal, 1+ as mild, 2+ as moderate, and 3+ as severe (19), see Table 1.

Table 1. Grading score of the ocular signs

Signs	Score 0	Score 1	Score 2	Score 3
Bulbar conjunctival hyperemia	Abscent	Mild	Moderate	Severe
Tarsal papillary hypertrophy	No	<1mm	1-3mm	>3mm
Limbal papillary hypertrophy	No	<3 h	3-6 h	>6 h
Corneal pannus	No	1 quadrant	2quadrants	> = 3 quadrants
Corneal punctate erosion	No	1 quadrant	2 quadrants	> = 3 quadrants
Corneal opacity	No	Peripheral	Mid-peripheral	Central

Management and follow-up

All medications including topical corticosteroids, antihistamines, mast cell stabilizers, vasoconstrictors, and non-steroidal anti-inflammatory drugs (NSAIDs) were discontinued at least 1 week before treatment. Only TAC 0.05% drop 4 times per day was started. The drop was continued 4 times per day for 1 month. The dose was then tapered according to ocular surface inflammation and subjective symptoms. The patients were kept on a minimum maintenance dose. The patients were visited on a regular basis on post-treatment days of 3, 7, 14, 28, and every month thereafter. Objective and subjective signs and symptoms were examined for alterations after one week, and one and six months of treatment (main follow up visits). Each main follow up visit contained complete eye examination, involving applanation tonometry, fluorescein

staining, slit-lamp biomicroscopy, and measurement of best spectacle-corrected visual acuity (BSCVA). All follow-up visits were recorded by digital photography (Imagenet; Topcon SL-8Z1; Tokyo, Japan). All patients were asked to report any discomfort caused by the use of TAC eye drops. Analyses were continued for probable systemic and ocular adverse effects. Determination of ocular safety was performed by measuring the alterations in IOP, visual acuity, and clinical outcomes for fundus, anterior chamber, lens and iris. Additionally, the tests including measurement of blood biochemical parameters, hematological analysis, and urinalysis were implemented before, and every three months after treatment.

Week 1	0	0 (.0)	4 (14.3)	0 (.0)	2 (7.1)	0 (.0)	8 (28.6)
	1	11 (39.3)	19 (67.9)	13 (46.4)	20 (71.4)	18 (64.3)	16 (57.1)
	2	16 (57.1)	4 (14.3)	13 (46.4)	4 (14.3)	8 (28.6)	2 (7.1)
	3	1 (3.6)	1 (3.6)	2 (7.1)	2 (7.1)	2 (7.1)	2 (7.1)
	P-values	.001	.029	.320	.029	.797	.440
Month 1	0	9 (32.1)	8 (28.6)	6 (21.4)	3 (10.7)	2 (7.1)	9 (32.1)
	1	14 (50.0)	16 (57.1)	20 (71.4)	21 (75.0)	22 (78.6)	15 (53.6)
	2	5 (17.9)	4 (14.3)	2 (7.1)	2 (7.1)	2 (7.1)	2 (7.1)
	3	0 (.0)	0 (.0)	0 (.0)	2 (7.1)	2 (7.1)	2 (7.1)
	P-values	<.001	.001	<.001	.003	.017	.122
Months 6	0	9 (32.1)	8 (28.6)	6 (21.4)	3 (10.7)	2 (7.1)	9 (32.1)
	1	15 (53.6)	16 (57.1)	20 (71.4)	21 (75.0)	22 (78.6)	15 (53.6)
	2	4 (14.3)	4 (14.3)	2 (7.1)	4 (14.3)	2 (7.1)	2 (7.1)
	3	0 (.0)	0 (.0)	0 (.0)	0 (.0)	2 (7.1)	2 (7.1)
	P-values	<.001	.001	<.001	.001	.017	.122

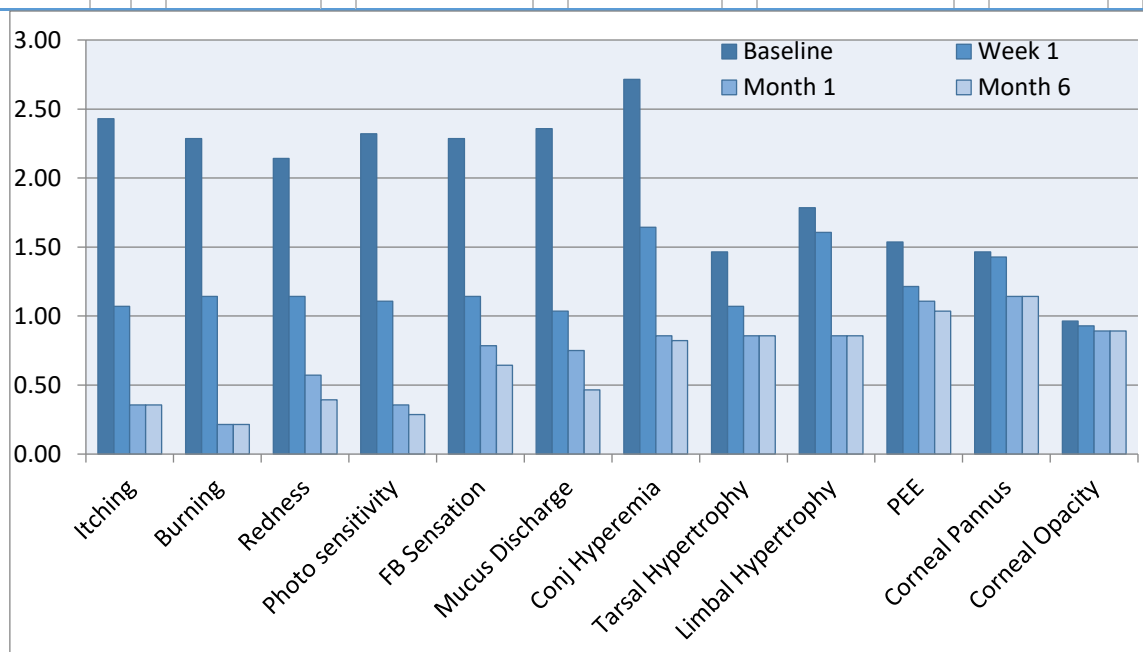


Chart 1. Distribution of subjective symptoms and objective signs scores at baseline, 1 week, 1 and 6 months after treatment.

DISCUSSION

According to our findings, the eye drop of 0.05% TAC suspension can be administrated safely and effectively for the treatment of VKC patient resistant to routine drugs of topical steroids. A significant improvement was found in the symptoms of inflammation without any

complications in all patients. There was no need for any extra drug like topical steroids to achieve more relief, which means the activity of this agent as a steroid-sparing medication. It should be noted that the prolonged administration of this drug may importantly control the disease.

Recently, there is special attention towards non-IgE-dependent mechanism in VKC pathogenesis. These studies suggest Th2-driven mechanism. T-cell clones are one of the main Th2- types and of VKC biopsies in the CD4 (28). Corneal damage is almost always due to a superficial keratopathy, corneal shield ulcers or neovascularization. Glaucoma and cataract are two serious ocular side effects of long standing steroid treatment (19). The chronic inflammation and long standing nature in the patients with limbal VKC can partially or completely cause limbal stem cell deficiency (LSCD), probably because of poor mechanical stromal support or serious damage to stem cells following toxic products from eosinophils and other inflammatory cells that penetrate into limbus (29).

TAC is a non-steroidal immune-modulator capable of blocking the calcineurin, thereby suppressing the synthesis of different cytokines through active T cells. TAC ointment is extensively effective to treat atopic dermatitis (21). The topical TAC in doses of 0.02–0.1% are reportedly useful to treat multiple refractory inflammatory diseases of the eye surface, such as VKC and atopic keratoconjunctivitis (AKC) (30). However, there is no information of optimum treatment dose and long-lasting impacts of the treatment at mentioned doses (31).

The immune responses are suppressed by TAC through the prevention of producing inflammatory cytokine (such as TNF- α , IFN- γ , IL-8, IL-5, IL-4, IL-3 and IL-2) as well as the down-regulation of expressing high-affinity IgE receptor I on the Langerhans cells with no side effect on the connective tissues (31). TAC (with a molecular weight of about 800 D) is a highly hydrophobic macrolide lactone. The penetration of TAC into the corneal epithelium is somewhat difficult due to its special properties and almost large molecular size, thus leading to accumulation in the corneal stroma and hence the low intraocular level of drug. It is certain that TAC will penetrate more easily than over a healthy eye surface following the rupture of the epithelial barrier in the cornea, possibly leading to successful treatment in severe cases of ocular surface inflammation

(31). Accordingly, topical TAC may theoretically lead to a better response in patients with conjunctival inflammation than in those with deeper inflammatory situations like uveitis and corneal transplant rejection (31, 32). TAC ointment 0.02%–0.1% has been applied to a variety of ocular surface autoimmune diseases. It shares several immunosuppressive properties with cyclosporine A (32). The inhibitory activity of cyclosporin on the T cell-mediated cytokine production is approximately 10-100 times less than that of TAC, thus the preparation of ophthalmic TAC can be stronger against the severe form of VKC and AKC (13,14).

Aqueous-insoluble TAC is commonly formulated as suspension. We used TAC 0.05% suspension to treat long standing steroid-resistant and steroid-dependent VKC cases with a medium-term follow-up. Improvement in all subjective symptoms occurred as early as 1 week after treatment but objective signs improved later nearly 1 month after treatment. Corneal neovascularization regressed slowly and less dramatically. Corneal opacity did not even change at all. No ocular or systemic adverse effects were found. Some investigators have studied the effectiveness of topical TAC to treat highly allergic ocular conditions. Different concentrations from 0.005% to 0.1% have been used (30). A multicenter double-blinded placebo-controlled randomized clinical trial was conducted to evaluate the effectiveness of TAC ophthalmic suspension 0.1% to treat highly allergic conjunctivitis. The TAC group showed better objective and subjective findings and symptoms compared to the placebo group (33).

Numerous studies documented the effectiveness of topical cyclosporine to treat highly allergic ocular conditions (25,34). Nevertheless, oil-based preparations with high cyclosporine concentration (such as castor oil) lead to the appearance of severe burning sensation and blurred vision during injection, which result in weak compliance (34).

Similar findings to our study results have previously been reported in many studies. In a study by Vichyanond et al., topical TAC

ointment 0.1% was applied to patients with recalcitrant VKC for a month (35). Kymionis et al. published a case report after applying TAC skin ointment 0.03% two times per day in a boy suffering from VKC-mediated giant papillary conjunctivitis, the results of which eliminated the giant papillae after 15 days, without any evidence of papillae after one-month treatment (36).

Refractory and steroid-dependent cases of VKC with favorable response to TAC drop may show kind of dependency to it which may be better than steroid dependency with lower doses and more safety. Even in some cases it may be used as monotherapy. To prevent irreversible sequelae of the cornea and limbus such as corneal opacification and limbal stem cell deficiency, topical immune-suppressive such as TAC suspension 0.05% may be better to apply earlier in long standing refractory and steroid-resistant VKC cases.

Some limitations of the present study were the small sample size and the lack of control group. We used TAC drop in a small series of patients with medium-term follow up. Despite that, our sample size and follow up period is longer than most of the published studies. Unavailability of TAC eye drop and ophthalmic ointments in most of the countries is a concern. Further randomized clinical trials with larger sample sizes and prolong follow-up periods are recommended to define its optimum concentration and treatment protocol.

In summary, topical tacrolimus 0.05% suspension was shown to be an effectiveness and safe agent to treat the refractory VKC. This drug is recommended to be prescribed prior to the appearance of side effects such as corneal opacity, irreversible deficiency in limbal stem cell, and steroid side effects. However, prolonged administration may be necessary to control the disease.

References

[1] Alemayehu AM, Yibekal BT, Fekadu SA. Prevalence of vernal keratoconjunctivitis and its associated factors among children

in Gambella town, southwest Ethiopia, June 2018. *PLoS One.* 2019; 14(4):e0215528.

- [2] Villegas BV, Benitez-Del-Castillo JM. Current Knowledge in Allergic Conjunctivitis. *Turk J Ophthalmol.* 2021; 51(1):45-54.
- [3] AlHarkan DH. Management of vernal keratoconjunctivitis in children in Saudi Arabia. *Oman J Ophthalmol.* 2020;13 (1):3-12.
- [4] Addis H, Jeng BH. Vernal keratoconjunctivitis. *Clin Ophthalmol.* 2018; 12:119-123.
- [5] Chatterjee A, Bandyopadhyay S, Kumar Bandyopadhyay S. Efficacy, Safety and Steroid-sparing Effect of Topical Cyclosporine A 0.05% for Vernal Keratoconjunctivitis in Indian Children. *J Ophthalmic Vis Res.* 2019;14(4):412-418.
- [6] Yazu H, Fukagawa K, Shimizu E, Sato Y, Fujishima H. Long-term outcomes of 0.1% tacrolimus eye drops in eyes with severe allergic conjunctival diseases. *Allergy Asthma Clin Immunol.* 2021;17(1):11.
- [7] Al-Amri AM, Fiorentini SF, Albarry MA, Bamahfouz AY. Long-term use of 0.003% tacrolimus suspension for treatment of vernal keratoconjunctivitis. *Oman J Ophthalmol.* 2017;10(3):145-149.
- [8] Foroutan A, Ghafourian A, Habibi A, Foroutan P, Ashrafkhorasani M, Alemzadeh SA. Successful treatment of allergic conjunctival granuloma by topical tacrolimus: A clinicopathologic case report. *Indian J Ophthalmol.* 2018;66(4):578-580.
- [9] Haddadi S, Shahrokhirad R, Ansar M M, et al. Efficacy of Preoperative Administration of Acetaminophen and Melatonin on Retrobulbar Block Associated Pain in Cataract Surgery, *Anesth Pain Med.* 2018 ; 8(5):e61041.
- [10] Akbari M, Moghadam RS, Elmi R, Nosrati A, Taghiabadi E, Aghdami N. Adjunctive Tacrolimus for Herpetic Stromal Keratitis. *J Ophthalmic Vis Res* 2019; 14: 400–411.
- [11] Fatima, Z. C. Chaurasia, R. & Singh, S.P. Evaluation of the Effects of 0.03% Tacrolimus on Schirmer Tear Test and Tear Film Break-Up Time in Patients of Chronic Dry Eye Disease. *International Journal of Contemporary Medical Research* 2018;5(2):B9-B13.

- [12] Bhargava, R. & Kumar, P. Comparison of the safety and efficacy of topical Tacrolimus (0.03%) versus dexamethasone (0.05%) for subepithelial infiltrates after adenoviral conjunctivitis. *Indian J Ophthalmol*, 2019; 67:594-8.
- [13] Siegla, C. König-Schustera, M. Nakowitsch, S. et al. Pharmacokinetics of topically applied tacrolimus dissolved in Marinosolv, a novel aqueous eye drop formulation. *European Journal of Pharmaceutics and Biopharmaceutics*, 2019; 134; pp: 88-95.
- [14] Iendo, V. L. et al. Topical tacrolimus for the treatment of severe allergic keratoconjunctivitis in children. *Arq Bras Oftalmol* 2017, 80 (4), pp.211-214.
- [15] Shoughy, S.S. Topical tacrolimus in anterior segment inflammatory disorders. *Eye and Vision* 2017, 4 (7); 7 pages.
- [16] Al-Amri, A. M. Fiorentini, S.F.F. Albarry, M.A. & Bamahfouz, A.Y. Long-term use of 0.003% tacrolimus suspension for treatment of vernal keratoconjunctivitis. *Oman J Ophthalmol*. 2017;10(3): 145–149.
- [17] Kumar, J. Dwivedi, Sh. Verma, A. & Kumar Pathak, A. Tacrolimus Ointment for Treatment of Vernal keratoconjunctivitis. *Journal of Dental and Medical Sciences* 2017; 16 (3), pp: 29-37.
- [18] Doan, S., Amat, F., Gabison, E. et al.. Omalizumab in Severe Refractory Vernal Keratoconjunctivitis in Children: Case Series and Review of the Literature. *Ophthalmol Ther* 2017; 6 (1): 195-206.
- [19] Kheirkhah A,Zavareh M, Farzbod F,Mahbod M,Behrouz MJ.Tpical 0.005%tacrolimus eye drop for refractory vernal keratoconjunctivitis. *Eye* 2011;25;872-880.
- [20] De Smedt, Wildner G, Kestelyn P. Vernal keratoconjunctivitis: an update. *Br J Ophthalmol*. 2013;97(1):9-14.
- [21] Fiorentini, S.F. & Khurram, D.. Therapeutic effects of topical 0.03% Tacrolimus ointment in children with refractory vernal keratoconjunctivitis in Middle East. *Saudi Journal of Ophthalmology* 2019, 33, 117–120.
- [22] Akbari M, Elmi R. Herpes simplex virus and human papillomavirus coinfections in hyperimmunoglobulin E syndrome presenting as a conjunctival mass lesion. *Case reports in medicine*. 2017; Article ID 1650841.
- [23] Dupuis P, Prokopich CL, Hynes A, Kim H. A contemporary look at allergic conjunctivitis. *Allergy Asthma Clin Immunol*. 2020;16:5. Published 2020 Jan 21. doi:10.1186/s13223-020-0403-9
- [24] Shoughy SS. Topical tacrolimus in anterior segment inflammatory disorders. *Eye Vis (Lond)*. 2017;4:7.
- [25] Chatterjee A, Bandyopadhyay S, Kumar Bandyopadhyay S. Efficacy, Safety and Steroid-sparing Effect of Topical Cyclosporine A 0.05% for Vernal Keratoconjunctivitis in Indian Children. *J Ophthalmic Vis Res*. 2019; 14(4):412-418.
- [26] Iosseliani DG, Bosha NS, Sandodze TS, Azarov AV, Semitko SP. The effect of revascularization of the internal Carotid artery on the Microcirculation of the eye. *J. Adv. Pharm. Educ. Res*. 2020;10(2):209-14
- [27] Almohanna M. A, Alazwari A.M, Alotaibi Z. A, Alotaibi M. F, Shuraym S. H, Alowayfi S. M., and et al. An Overview of Red Eye diagnostic and Management Approach in Primary Health care center: Literature Review. *Int. J. Pharm. Phytopharmacol. Res*. 2020;10(6):115-19
- [28] De Smedt S, Wildner G, Kestelyn P. Vernal keratoconjunctivitis: an update. *Br J Ophthalmol*. 2013 Jan;97(1):9-14.
- [29] Baradaran-Rafii A, Akbari M, Shirzadeh E, Shams M. Single block conjunctival limbal autograft for unilateral total limbal stem cell deficiency. *Journal of ophthalmic & vision research*. 2015; 10(1):90-2.
- [30] Flynn T, Dahlmann-Noor A, Bunce C, Tuft S. Topical treatments for vernal keratoconjunctivitis. *Cochrane Database Syst Rev*. 2017;2017(8):CD010466.
- [31] Kandikattu HK, Mishra A. Immunomodulatory effects of tacrolimus (FK506) for the treatment of allergic diseases. *Int J Cell Biol Physiol*. 2018; 1(1-2):5-13.
- [32] Pucci N, Caputo R, di Grande L, et al. Tacrolimus vs. cyclosporine eye drops in severe cyclosporine-resistant vernal keratoconjunctivitis: a randomized, comparative, double-blind, crossover study. *Pediatr Allergy Immunol*. 2015; 26: 256–261.

- [33] Ohashi Y, Ebihara N, Fujishima H, et al. A randomized, placebo-controlled clinical trial of tacrolimus ophthalmic suspension 0.1% in severe allergic conjunctivitis. *J Ocul Pharmacol Ther.* 2010; 26:165-74.
- [34] Vichyanond P, Kosrirukvongs P. Use of cyclosporine A and tacrolimus in treatment of vernal keratoconjunctivitis. *Curr Allergy Asthma Rep.* 2013; 13: 308–314.
- [35] Vichyanond P, Tantimongkolsuk C, Dumrongkigchaiporn P, Jirapongsananuruk O, Visitsunthorn N, Kosrirukvongs P. Vernal keratoconjunctivitis: result of a novel therapy with 0.1% topical ophthalmic FK-506 ointment. *J Allergy Clin Immunol* 2004; 113(2): 355–358.
- [36] Kymionis GD, Goldman D, Ide T, Yoo SH. Tacrolimus ointment 0.03% in the eye for treatment of giant papillary conjunctivitis. *Cornea* 2008; 27(2): 228–229.